

子宫颈原发弥漫大B细胞淋巴瘤1例并文献复习

张佳玉^{1*}, 王肖琳^{2*}, 李承军¹, 肖燕¹, 王廷萱¹, 王伟^{3#}

¹青岛大学医学部, 山东 青岛

²日照市人民医院血液科, 山东 日照

³青岛大学附属医院血液科, 山东 青岛

收稿日期: 2023年10月23日; 录用日期: 2023年11月17日; 发布日期: 2023年11月23日

摘要

宫颈原发的非霍奇淋巴瘤十分罕见, 因临床表现无特异性, 常常与女性生殖系统其他恶性肿瘤混淆。弥漫大B细胞淋巴瘤是最常见的亚型, 及时的诊断及干预治疗, 患者预后通常良好。我们报道了1例原发宫颈弥漫大B细胞淋巴瘤的患者, 她因为阴道触及赘生物并伴腹痛入院, 行肿物的活检, 诊断为弥漫大B细胞淋巴瘤。随后行骨髓穿刺排除了骨髓受累, PET/CT可见子宫颈62 × 74 mm软组织肿块, 向上侵及子宫体, 左侧宫旁间隙可见软组织密度斑片, 侵及左侧附件, 腹膜后腹主动脉左旁轻度增大淋巴结。结合她的检查, 明确诊断为子宫颈原发弥漫大B细胞淋巴瘤, 分期IIE期。治疗上给予R-CHOP方案化疗, 在第三疗程结束时行PET/CT评估病情显示CR, 继续给予患者4周期化疗。从明确诊断截至到目前我们随访了8月, 患者疾病依然缓解。

关键词

淋巴瘤, 子宫颈, 诊断, 治疗

A Case of Primary Diffuse Large B-Cell Lymphoma of the Uterine Cervix and Review of the Literature

Jiayu Zhang^{1*}, Xiaolin Wang^{2*}, Chengjun Li¹, Yan Xiao¹, Tingxuan Wang¹, Wei Wang^{3#}

¹Medical College, Qingdao University, Qingdao Shandong

²Department of Hematology, Rizhao People's Hospital, Rizhao Shandong

³Department of Hematology, The Affiliated Hospital of Qingdao University, Qingdao Shandong

Received: Oct. 23rd, 2023; accepted: Nov. 17th, 2023; published: Nov. 23rd, 2023

*共同第一作者。

#通讯作者。

文章引用: 张佳玉, 王肖琳, 李承军, 肖燕, 王廷萱, 王伟. 子宫颈原发弥漫大 B 细胞淋巴瘤 1 例并文献复习[J]. 临床医学进展, 2023, 13(11): 18232-18241. DOI: 10.12677/acm.2023.13112558

Abstract

Primary non-Hodgkin's lymphoma of the cervix is very rare and is often confused with other malignant tumors of the female reproductive system because of the nonspecific clinical presentation. Diffuse large B-cell lymphoma is the most common subtype, and patients usually have a favorable prognosis with timely diagnosis and interventional therapy. We report a case of primary cervical diffuse large B-cell lymphoma in a patient who was admitted to the hospital for vaginal palpation of a bulky mass with abdominal pain and underwent biopsy of the mass, which led to the diagnosis of diffuse large B-cell lymphoma. Subsequently, a bone marrow aspiration was performed to rule out bone marrow involvement, and PET/CT revealed a 62 × 74 mm soft tissue mass in the cervix that invaded the uterine body upward, a soft tissue density patch in the left parietal space that invaded the left adnexa, and mildly enlarged lymph nodes on the left side of the retroperitoneal abdominal aorta. Combined with her examination, a definitive diagnosis of primary diffuse large B-cell lymphoma of the uterine cervix with stage IIE was made. She was treated with R-CHOP regimen chemotherapy, and at the end of the third course of treatment, PET/CT was performed to evaluate the disease showing CR, and the patient was continued to be given 4 cycles of chemotherapy. From the time of definitive diagnosis up to now we have followed the patient for 8 months and the patient is still in remission.

Keywords

Lymphoma, Uterine Cervix, Diagnosis, Treatment

Copyright © 2023 by author(s) and Hans Publishers Inc.

This work is licensed under the Creative Commons Attribution International License (CC BY 4.0).

<http://creativecommons.org/licenses/by/4.0/>



Open Access

1. 引言

淋巴瘤是原发于淋巴结或结外淋巴组织中淋巴细胞的恶性肿瘤[1]，当结外部位是疾病的唯一部位或大部分局限于结外部位时，可称为原发性结外非霍奇金淋巴瘤[2]。原发于结外的淋巴瘤约占了淋巴瘤患者的三分之一，对于弥漫大B细胞淋巴瘤而言，最常累积的结外器官是胃肠道，其次是骨骼、脾脏、骨髓、肾/肾上腺、肺、乳房、肝脏、胰腺、睾丸、中枢神经系统、甲状腺、皮肤、鼻腔[3]，女性生殖道成为结外淋巴瘤的原发部位是十分罕见的，约占0.5%~1.5% [4]，主要可累及附件、子宫体、子宫颈、阴道及外阴，在临床上，原发女性生殖系统淋巴瘤(primary female genital system lymphoma, PFGSL)主要发生于卵巢，而原发于子宫颈少见，在所有的子宫颈肿瘤中，只有0.008%为原发的淋巴瘤[5]。现阶段关于子宫颈原发淋巴瘤(primary lymphoma of the uterine cervix, LUCX)的相关文献主要以个案报道为主，因其罕见性，目前没有与治疗相关的标准诊疗，主要以化疗为主，单独化疗或化疗结合放疗是目前较常见的治疗方案，此外还有化疗结合免疫治疗、手术等。在此我们报告了1例诊断为子宫颈原发弥漫大B细胞淋巴瘤的患者。

2. 病例报告

一名62岁的绝经后妇女因“阴道扪及赘生物半个月”入院，患者伴有腹痛，没有阴道异常出血及分泌物，既往因为卵巢肿瘤行右侧附件切除术。行妇科检查发现阴道前壁距外口约2 cm处见一直径约2 cm

肿物，宫颈轻度糜烂，子宫及双附件触诊不清(见图 1)。宫颈细胞筛查未见明显异常。为了进一步明确肿物性质，于阴道镜下行肿物活检，结果考虑小圆细胞恶性肿瘤。免疫结果：CD10 (+)、Bcl-2 (弱+, 30%)、Bcl-6 (+, 90%)、MUM1 (+)、c-Myc (+, 90%)、CyclinD1 (-)、CD21 (-)、CD38 (+)、CD30 (-)、CD5 (-)、P53 (+, 80%)、Ki-67 (+, 90%)、CD79a 弥漫(+)、CD19 弥漫(+)、EBER (原位杂交) (-)、ALK (OTI1H7) (-)，符合弥漫大 B 细胞淋巴瘤，生发中心型；流式细胞学示 p53 (-)，MYC (+)，BCL2 (-)，BCL6 (-)。完善 PET/CT 显示子宫颈软组织密度肿块，向上侵及子宫体，边界不清，部分层面与临近膀胱分界不清，最大横截面约 62 × 74 mm，代谢异常增高，SUVmax 约 51.6；左侧宫旁间隙软组织密度斑片，侵及左侧附件并分界不清，代谢明显增高，SUVmax 约 23.6；左侧阴道下段局部结节状代谢增高灶，SUVmax 约 5.1，腹膜后腹主动脉左旁轻度增大淋巴结，直径约 8.0 mm，代谢轻度增高，SUVmax 约 2.5，考虑子宫颈淋巴瘤并左侧宫旁浸润、侵及左侧卵巢可能性大，同时因为肿块的压迫，她的左侧输尿管轻度梗阻，伴有轻度的左肾积水(见图 2)。骨髓穿刺未见骨髓受累。至此，患者明确诊断为子宫颈原发弥漫大 B 细胞淋巴瘤。治疗上给予患者 R-CHOP (利妥昔单抗 0.7 g，环磷酰胺 1.2 g，多柔比星脂质体 40 mg，长春地辛 4 mg，醋酸泼尼松 100 mg) 方案化疗，3 周期治疗后行 PET/CT 显示患者子宫颈肿块大软组织消失，子宫大小、形态可，左侧附件饱满，未见异常密度及异常代谢，腹膜后腹主动脉左旁淋巴结未见明显异常代谢，较前体积减小，代谢减低。随后她又完成了 4 周期的化疗。从诊断到目前我们随访 8 个月，患者症状缓解。

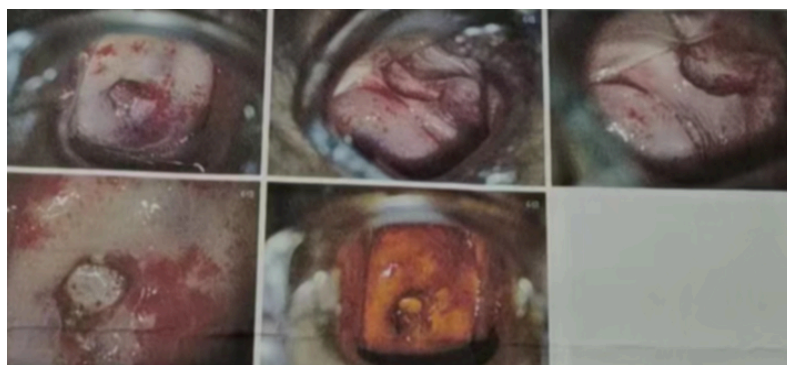

Figure 1. Colposcopic image of the patient

图 1. 患者阴道镜检查图像

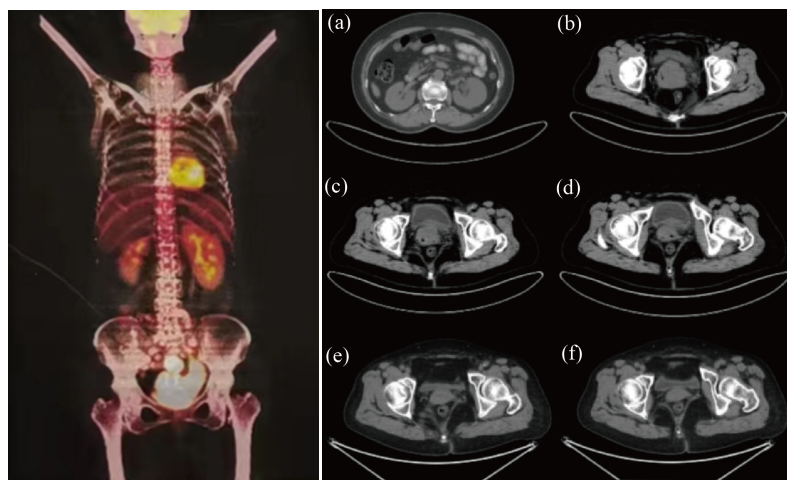


Figure 2. PET/CT images of the patient

图 2. 患者 PET/CT 图像

3. 文献综述

我们在 Pubmed 上在标题/摘要字段中应用不同关键词的组合, 包括“淋巴瘤”、“子宫颈”、“B 细胞淋巴瘤”、“子宫”, 广泛检索了从 2013 年至今的相关 LUCX 报道, 文章类型没有限制, 共检索到 36 篇相关文献, 筛选出 42 名诊断为原发性子宫颈淋巴瘤患者(见表 1)。患者的年龄在 22~84 岁之间, 平均年龄 51 岁。病理类型弥漫大 B 细胞淋巴瘤 73.81%, 滤泡性淋巴瘤占 4.76%, 伯基特淋巴瘤占 2.38%, 外周 T 细胞淋巴瘤 4.76%, 子宫粘膜相关淋巴组织(MALT)结节外边缘区淋巴瘤(EMZL)占 2.38%, 鼻型 NK/T 细胞淋巴瘤占 4.76%, 结节淋巴细胞为主型的霍奇金淋巴瘤占 2.38%, 还有 2 例文章中并未表明类型的非霍奇金淋巴瘤。临床表现为无症状患者占 11.90%, 最常见的临床症状为阴道出血, 占 54.76%, 其中有 1 人伴多发性单神经炎, 3 人存在盆腔疼痛, 1 人伴有体重减轻, 1 人伴有阴道异常分泌物; 腹痛占 7.14%; 性交后出血占 11.90%, 其中 1 人伴有水样阴道分泌物和排便困难; 阴道恶臭分泌物占 2.38%; 由于肿物压迫表现为尿频、排尿困难占 7.14%; 还有 1 名年轻患者因停经就诊, 这可能因为阴道或宫颈管阻塞导致; 1 人初发症状为下肢深静脉血栓导致的双下肢肿胀疼痛。在报告的患者中, 几乎没有患者存在 B 症状; 在分期上, IE 期占 51.61%, IIE 期占 32.26%, IV 期占 16.13%; 大多数患者治疗单独采用 R-CHOP 化疗方式便获得良好的效果, 仅有 1 例患者在 3 周期 R-CHOP 化疗后宫颈仅有轻度减小, 进一步采用了子宫和双侧输卵管切除; 同时治疗方案还有化疗联合放疗、化疗联合免疫治疗及手术治疗, 放疗被可作为化疗的辅助手段, 使疾病获得了长期缓解; 有 7 例患者采取了全子宫切除, 其中 4 名患者在切除后行化疗辅助治疗预防复发, 值得注意的是, 1 名诊断为伯基特淋巴瘤的患者在化疗进展后进行了 CAR-T 治疗, 后行造血干细胞移植, 这为治疗积累了新的经验[6]。从患者的生存情况来看, 我们尚未明显看出手术治疗优于非手术治疗。对提供了随访数据的 29 名患者进行生存分析(见图 3), 中位随访时间为 24 月, 有 4 名患者在因疾病去世, 其中 1 例患者出现了中枢神经系统受累表现(见表 2), 在所有病理类型中, 弥漫大 B 细胞淋巴瘤及滤泡淋巴瘤患者预后良好。

Table 1. Age, chief complaint, pathologic type and stage of patients with primary lymphoma of the cervix in the literature
表 1. 文献中子宫颈原发淋巴瘤患者的年龄、主诉、病理类型及分期

序号	年龄	临床表现	病理诊断	分期
1 [7]	54	无症状	滤泡性淋巴瘤	IEA
2 [8]	47	阴道出血	伯基特淋巴瘤	II
3 [9]	49	无症状	弥漫大 B 淋巴瘤	IE
4 [10]	71	尿频、排尿困难	弥漫大 B 淋巴瘤	IVB
5 [11]	84	阴道大量出血	弥漫大 B 淋巴瘤	IEA
6 [12]	75	阴道出血	弥漫大 B 淋巴瘤	IE
7 [13]	30	阴道出血	弥漫大 B 淋巴瘤	IEB
8 [14]	47	阴道出血、面神经麻痹	外周 T 细胞淋巴瘤	-
9 [15]	38	性交后出血	弥漫大 B 淋巴瘤	IE
10 [15]	30	性交后出血、异常分泌物	弥漫大 B 淋巴瘤	IIE
11 [16]	54	阴道出血、盆腔疼痛	弥漫大 B 淋巴瘤	IE
12 [17]	47	接触出血	弥漫大 B 淋巴瘤	IIEA
13 [18]	40	性交后出血、水样分泌物	非霍奇金淋巴瘤	-
14 [19]	54	无症状	弥漫大 B 淋巴瘤	-

Continued

15 [20]	46	阴道流血	弥漫大 B 淋巴瘤	IE
16 [21]	50	无症状	弥漫大 B 淋巴瘤	IV
17 [21]	46	阴道异常出血	弥漫大 B 淋巴瘤	IIB
18 [22]	52	阴道流血	弥漫大 B 淋巴瘤	IEA
19 [22]	50	阴道流血	弥漫大 B 淋巴瘤	IE
20 [22]	39	恶臭分泌物	弥漫大 B 淋巴瘤	IEAX
21 [22]	62	阴道流血	弥漫大 B 淋巴瘤	IIE
22 [23]	36	阴道出血、盆腔疼痛、排尿困难	弥漫大 B 淋巴瘤	IV
23 [24]	55	阴道出血	弥漫大 B 淋巴瘤	-
24 [25]	74	无症状	弥漫大 B 淋巴瘤	IIEA
25 [26]	71	阴道出血	结节外边缘区淋巴瘤	II
26 [27]	51	阴道出血	弥漫大 B 淋巴瘤	IE
27 [28]	69	刺激性排尿、微量血尿	弥漫大 B 淋巴瘤	-
28 [29]	40	下肢深静脉血栓导致右下肢肿胀疼痛	弥漫大 B 淋巴瘤	IIE
29 [30]	61	阴道出血、体重下降	弥漫大 B 淋巴瘤	IV
30 [31]	31	停经 8 周	弥漫大 B 淋巴瘤	-
31 [32]	39	阴道出血	弥漫大 B 淋巴瘤	IEA
32 [33]	34	腹痛	弥漫大 B 淋巴瘤	-
33 [33]	77	发热、腹痛	弥漫大 B 淋巴瘤	-
34 [34]	37	性交后出血	滤泡性淋巴瘤	IEA
35 [35]	65	阴道出血	鼻型 NK/T 细胞淋巴瘤	-
36 [36]	22	骨盆疼痛、左下肢水肿、腹围增大	弥漫大 B 淋巴瘤	IIE
37 [37]	43	阴道出血	结节淋巴细胞为主的霍奇金淋巴瘤	IE
38 [38]	54	排尿困难	鼻型 NK/T 细胞淋巴瘤	-
39 [39]	49	性交后出血，月经过多	非霍奇金淋巴瘤	IEA
40 [40]	49	阴道出血，腹痛	外周 T 细胞淋巴瘤	-
41 [41]	44	阴道出血	弥漫大 B 淋巴瘤	IVEA
42 [42]	79	阴道出血	弥漫大 B 淋巴瘤	IIE

Table 2. Treatment, follow-up time and survival status of patients with primary lymphoma of the cervix in the literature
表 2. 文献中子宫颈原发淋巴瘤患者的治疗、随访时间及生存状态

序号	治疗	随访(月)	状态
1	R + 宫颈锥切	24	Alive
2	HyperCVAD-A/B、GDP、CAT-T、异体干细胞移植	8	Dead
3	R-CHOP	-	Alive
4	R-CHOP	-	Dead
5	宫腔镜切除 + 放疗	20	Alive

Continued

6	CHOP + 放疗	29	Alive
7	R-CHOP + 亮丙瑞林	-	Alive
8	环磷酰胺、依托泊苷和类固醇	0.25	Dead
9	R-CHOP	-	Alive
10	R-CHOP	12	Alive
11	R-CHOP + 放疗	24	Alive
12	R-CHOP	36	Alive
13	R-CHOP	6	Alive
14	子宫输卵管切除术加淋巴结切除 + R-CHOP	-	Alive
15	CHOP + 放疗	-	Alive
16	R-CHOP	6	Alive
17	R-CHOP	42	Alive
18	R-CHOP + 放疗	18	Alive
19	R-CHOP + 放疗	43	Alive
20	R-CHOP + 放疗	8	Alive
21	R-CEOP + 放疗	10	Alive
22	R-CHOP	15	Alive
23	R-CHOP + 子宫切除术和双侧输卵管切除	36	Alive
24	R-CHOP	-	Alive
25	R-CHOP	9	Alive
26	R-CHOP	24	Alive
27	R-CHOP	-	-
28	R-CHOP	45	Alive
29	R-CHOP + 放疗	-	-
30	R-CHOP	-	-
31	全子宫切除术 + R-CHOP	48	Alive
32	R-CHOP + 放疗	60	Alive
33	R-CHOP + 放疗	36	Alive
34	子宫切除并保留双侧附件	12	Alive
35	CHOP + 依托泊苷	4	Dead
36	R-CHOP	化疗 5 周期	Alive
37	子宫切除术 + ABVD	12	Alive
38	子宫切除术和单侧输卵管卵巢切除术	2	-
39	CHOP + 放疗	192	Alive
40	CHOP	20	Dead
41	R-CHOP	24	Alive
42	-	-	-

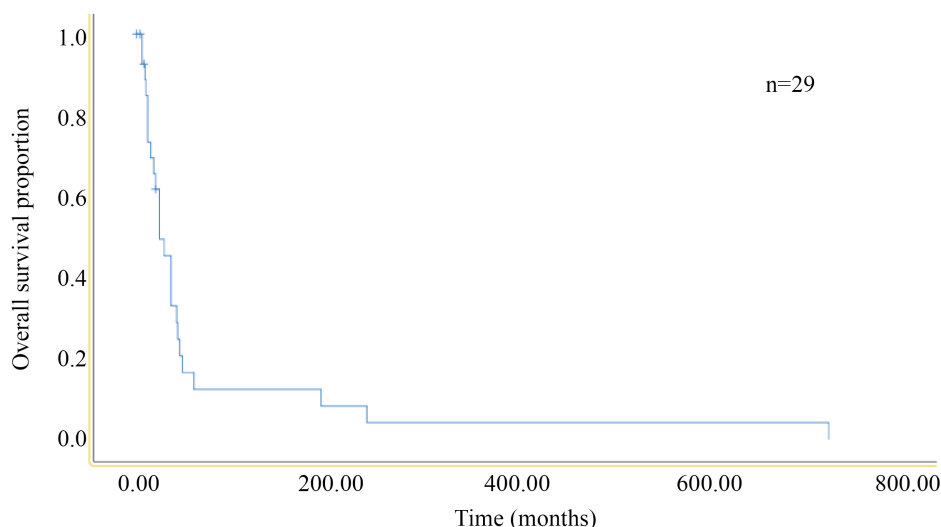


Figure 3. Survival analysis of patients with primary lymphoma of the cervix collected in the literature

图 3. 文献中收集到的子宫颈原发淋巴瘤患者的生存分析

4. 讨论

对于 LUCX 的诊断需要满足：1) 在初诊时，疾病进程局限于女性生殖道；2) 全身其他部位没有疾病存在；3) 在外周血及骨髓中没有发现任何异常的白血病细胞；4) 在 6 个月内没有其他远端器官受累 [43]。我们的这名患者在行 PET/CT 及骨髓穿刺后排除了其他部位存在疾病，符合子宫颈原发淋巴瘤的诊断。

LUCX 的病因并不明确，可能与慢性炎症、HPV 感染及免疫缺陷和免疫逃逸相关 [44]。其常见的临床症状是异常的阴道出血，还包括了性交后出血、阴道分泌物、盆腔疼痛等 [5] [45]，一项对 697 例原发女性生殖系统淋巴瘤的分析中显示，最常见的病理类型为弥漫大 B 细胞淋巴瘤，其次为滤泡性淋巴瘤、伯基特淋巴瘤和粘膜相关淋巴组织淋巴瘤 [46]。虽然常见的病理类型为弥漫大 B 细胞淋巴瘤，但常常不存在 B 症状(发热、疲劳、体重减轻、盗汗)，这与我们回顾文献得出的结论一致 [41]。因其罕见性和缺乏临床特征性表现，与其他恶性肿瘤鉴别起来相对困难，容易误诊。影像学检查包括了超声、MR、CT、PET/CT 等 [47]，MR 具有出色的空间分辨率和组织对比度，可以用于肿瘤的分界，与 MR 相比，超声更加便捷，具有更广泛的应用；PET/CT 在对疾病进行分期和评估治疗反应上有着重要的地位，它可以定位识别淋巴瘤的位置，识别有无淋巴结和骨髓的受累及检测肿瘤有无远处转移 [48]。由于肿瘤细胞起源于宫颈间质，被鳞状上皮细胞覆盖，宫颈细胞学检查通常呈阴性，诊断需要对宫颈进行深度的活检，在我们的文献回顾中，仅一位患者通过巴氏涂片筛查得到异常结果，因此活检和免疫组化对于区分子宫颈原发淋巴瘤和其他恶性肿瘤是非常重要的。对于 LUCX 的分期，Ann Arbor 分期系统和国际妇产科联合会(the International Federation of Gynecology and Obstetrics, FIGO)分期系统皆可，部分研究称 Ann Arbor 分期系统的敏感性更高，其中最常见的是 IE 期 [4]。

在治疗上，由于原发于女性生殖系统的淋巴瘤十分罕见，尚没有相关指南规定的标准疗法，目前治疗的基石仍然是化疗 [12]。在确诊后通常应用淋巴瘤的标准化疗方案，大多数病例中采用单独的化疗或放疗联合化疗，非霍奇金淋巴瘤以 CHOP 为基础的化疗联合中等剂量的放疗是最有效的治疗方式 [49]，放疗可以避免全身的并发症。手术也是一种治疗方式，包括了全子宫切除，联合或不联合输卵管、卵巢切除及淋巴结清扫，但是尚未证明根治性手术是有利的，在 Guglielmo Stabile [11] 等人报告的 1 例分期为

IE 的宫颈原发的弥漫大 B 细胞淋巴瘤病例中, 对患者采用了宫腔镜下病变部位的切除, 术后仅进行局部放疗, 在诊断后的 24 个月患者疾病没有进展。对于未孕绝经前女性, 保留生育能力也是十分重要的话题, 首选化疗和免疫疗法是安全的, GnRH 激动剂的应用可能降低卵巢早衰风险, 卵巢转位也可降低患者放疗时对生育能力的损害[23], 在我们回顾的文献中, 一名年轻患者采用了 R-CHOP 联合 GnRH 激动剂治疗, 在治疗后 1 年自然受孕并成功经阴道分娩。此外保留生育能力的手术是可行的[5], 如冷刀锥切术、宫腔镜切除术等。目前尚无证据表明根治性手术比保守手术更具有生存优势。

我们可以在上表中看到大多数患者拥有良好的生存率, 在 Xin Weng 等人的研究中患者的 5 年 OS 可达到 93.5% [44]。它的预后取决于组织学类型、分期及治疗方式。IE 期的患者的五年生存率(89%)要优于 IIE-IV 期的患者(20%) [50], 如若在疾病的早期及时发现并且给予干预治疗, 患者可以取得良好的预后, 其他与预后相关的指标还有血红蛋白、乳酸脱氢酶水平、受累淋巴结数量等。此外, 患者还可出现中枢神经系统的复发, 这类患者往往预后差, 因此在治疗过程中进行中枢预防也很重要[51]。

参考文献

- [1] Song, Y., Wu, S.J., Shen, Z., *et al.* (2023) Chinese Expert Consensus on Bruton Tyrosine Kinase Inhibitors in the Treatment of B-Cell Malignancies. *Experimental Hematology & Oncology*, **12**, Article No. 92. <https://doi.org/10.1186/s40164-023-00448-5>
- [2] Yang, H., Xun, Y., Ke, C., *et al.* (2023) Extranodal Lymphoma: Pathogenesis, Diagnosis and Treatment. *Molecular Biomedicine*, **4**, Article No. 29. <https://doi.org/10.1186/s43556-023-00141-3>
- [3] Shen, R., Xu, P.P., Wang, N., *et al.* (2020) Influence of Oncogenic Mutations and Tumor Microenvironment Alterations on Extranodal Invasion in Diffuse Large B-Cell Lymphoma. *Clinical and Translational Medicine*, **10**, e221. <https://doi.org/10.1002/ctm2.221>
- [4] Hariprasad, R., Kumar, L., Bhatla, D.M., *et al.* (2006) Primary Uterine lymphoma: Report of 2 Cases and Review of Literature. *American Journal of Obstetrics and Gynecology*, **195**, 308-313. <https://doi.org/10.1016/j.ajog.2006.04.002>
- [5] Stabile, G., Ripepi, C., Sancin, L., *et al.* (2023) Management of Primary Uterine Cervix B-Cell Lymphoma Stage IE and Fertility Sparing Outcome: A Systematic Review of the Literature. *Cancers*, **15**, Article No. 3679. <https://doi.org/10.3390/cancers15143679>
- [6] Lionel, A.C. and Westin, J. (2023) Evolving Role of CAR T Cell Therapy in First- and Second-Line Treatment of Large B Cell Lymphoma. *Current Oncology Reports*, **25**, 1387-1396.
- [7] Matsas, A., Christopoulos, P., Karachalios, C., *et al.* (2023) Primary Follicular Lymphoma of the Uterine Cervix: A Case Report. *Oncology Letters*, **25**, Article No. 251. <https://doi.org/10.3892/ol.2023.13837>
- [8] Cheng, L., Huang, M., Cao, Y., *et al.* (2022) Allogeneic CAR-T Bridging to allo-HSCT as a Treatment Strategy for Refractory Adult Burkitt's Lymphoma: A Case Report. *Translational Cancer Research*, **11**, 2996-3002. <https://doi.org/10.21037/tcr-22-174>
- [9] Arshad, I. and Kafeel, M. (2022) Primary Endometrial Diffuse Large B-Cell Lymphoma: A Rare Disease and Diagnostic Challenge in an Asymptomatic Postmenopausal Woman. *Cureus*, **14**, e24592. <https://doi.org/10.7759/cureus.24592>
- [10] Li, J., Zhang, X., Liu, Y., *et al.* (2022) Primary Diffuse Large B-Cell Lymphoma of the Uterine Cervix with Severe Lower Urinary Tract Symptoms: A Rare Case Report and Review of the Literature. *Gynecologic Oncology Reports*, **43**, Article ID: 101066. <https://doi.org/10.1016/j.gore.2022.101066>
- [11] Stabile, G., Sancin, L., Boschian Bailo, P., *et al.* (2022) Hysteroscopic Resection Followed by Adjuvant Radiotherapy: Report of a New Therapeutic Approach to Primary Cervical Diffuse Large B-Cell Lymphoma. *International Journal of Environmental Research and Public Health*, **19**, Article No. 11779. <https://doi.org/10.3390/ijerph191811779>
- [12] Capsa, C., Calustian, L.A., Antoniu, S.A., *et al.* (2022) Primary Non-Hodgkin Uterine Lymphoma of the Cervix: A Literature Review. *Medicina (Kaunas, Lithuania)*, **58**, Article No. 106. <https://doi.org/10.3390/medicina58010106>
- [13] Quaresima, P., Saccone, G., Zuccalà, V., *et al.* (2022) Successful Vaginal Delivery after Induction of Labour in a Patient Treated for Non-Hodgkin's Lymphoma of the Cervix: A Case Report and Literature Review. *Case Reports in Obstetrics and Gynecology*, **2022**, Article ID: 3541046. <https://doi.org/10.1155/2022/3541046>
- [14] Seal, R., Parkhi, M., Kumar, R., *et al.* (2022) Primary Peripheral T-Cell Lymphoma of the Cervix with Mononeuritis Multiplex: An Unusual Case Presentation. *Autopsy & Case Reports*, **12**, e2021354. <https://doi.org/10.4322/acr.2021.354>

- [15] Aminimoghaddam, S., Salarifar, E. and Noei Teymoordash, S. (2022) Primary Large B-Cell Lymphoma of the Cervix: A Case Report and Review of Literature. *Clinical Case Reports*, **10**, e05639. <https://doi.org/10.1002/ccr3.5639>
- [16] Akkour, K., Alhulwah, M., Alhalal, H., et al. (2021) Primary Extranodal Diffuse Large B-Cell Lymphoma of the Uterine Cervix. *The Malaysian Journal of Pathology*, **43**, 327-331.
- [17] Yoshida, Y., Izumi, R., Iwashita, S., et al. (2020) Malignant Lymphoma of the Cervix in a Bicollis Uterus Considered to Be a Post-Transplant Lymphoproliferative Disorder in a Patient after Renal Transplantation: A Case Report. *Gynecologic Oncology Reports*, **34**, Article ID: 100676. <https://doi.org/10.1016/j.gore.2020.100676>
- [18] Birge, Ö., Bakır, M.S., Dinc, C., et al. (2021) Uterine Cervical Involvement of Non-Hodgkin Lymphoma: Rare Cause of Postcoital Bleeding. *Clinical Case Reports*, **9**, e04150. <https://doi.org/10.1002/ccr3.4150>
- [19] Desana, B., Balbo Mussetto, A., Macera, A., et al. (2021) Rare Case of Uterine Cervix Lymphoma with Spontaneous Regression: Case Report. *The Journal of Obstetrics and Gynaecology Research*, **47**, 807-811. <https://doi.org/10.1111/jog.14562>
- [20] Selvi Demirtas, G., Gokcu, M., Sancı, M., et al. (2020) Primary Non-Hodgkin's Lymphoma Masquerading as Cervical Cancer. *Ginekologia Polska*, **91**, 571. <https://doi.org/10.5603/GP.2020.0090>
- [21] Murata, H., Nakamura, H., Ohta, Y., et al. (2020) Two Cases of Spindle Cell Variant Diffuse Large B-Cell Lymphoma of the Uterine Cervix. *Gynecologic Oncology Reports*, **33**, Article ID: 100611. <https://doi.org/10.1016/j.gore.2020.100611>
- [22] Goda, J.S., Gaikwad, U., Narayan, A., et al. (2020) Primary Diffuse Large B Cell Lymphoma of Uterine Cervix: Treatment Outcomes of a Rare Entity with Literature Review. *Cancer Reports (Hoboken, N.J.)*, **3**, e1264. <https://doi.org/10.1002/cnr2.1264>
- [23] Del, M., Angeles, M.A., Syrykh, C., et al. (2020) Primary B-Cell Lymphoma of the Uterine Cervix Presenting with Right Ureter Hydronephrosis: A Case Report. *Gynecologic Oncology Reports*, **34**, Article ID: 100639. <https://doi.org/10.1016/j.gore.2020.100639>
- [24] Roberts, M.E. and Cottrill, H.M. (2018) A Case of Primary Cervical Lymphoma in a Patient with Abnormal Uterine Bleeding. *Gynecologic Oncology Reports*, **26**, 105-107. <https://doi.org/10.1016/j.gore.2018.10.014>
- [25] Koyanagi, T., Kondo, H., Toyama, A., et al. (2018) Malignant Lymphoma of the Uterine Cervix Presumptively Diagnosed by Pap Smear: A Case Report. *Oncology Letters*, **15**, 6678-6680. <https://doi.org/10.3892/ol.2018.8146>
- [26] Takimoto, T., Maegawa, S., Tatsumi, H., et al. (2017) Extranodal Marginal Zone Lymphoma of the Uterine Cervix with Concomitant Copy Number Gains of the MALT1 and BCL2 Genes: A Case Report. *Oncology Letters*, **13**, 3641-3645. <https://doi.org/10.3892/ol.2017.5944>
- [27] Cubo, A.M., Soto, Z.M., Cruz, M., et al. (2017) Primary Diffuse Large B Cell Lymphoma of the Uterine Cervix Successfully Treated by Combined Chemotherapy Alone: A Case Report. *Medicine*, **96**, e6846. <https://doi.org/10.1097/MD.00000000000006846>
- [28] Yang, G., Deisch, J., Tavares, M., et al. (2017) Primary B-Cell Lymphoma of the Uterine Cervix: Presentation in Pap-Test Slide and Cervical Biopsy. *Diagnostic Cytopathology*, **45**, 235-238. <https://doi.org/10.1002/dc.23627>
- [29] Regalo, A., Caseiro, L., Pereira, E., et al. (2016) Primary Lymphoma of the Uterine Cervix: A Rare Constellation of Symptoms. *BMJ Case Reports*, **2016**, 1-2. <https://doi.org/10.1136/bcr-2016-216597>
- [30] Sharma, V., Dora, T., Patel, M., et al. (2016) Case Report of Diffuse Large B Cell Lymphoma of Uterine Cervix Treated at a Semiurban Cancer Centre in North India. *Case Reports in Hematology*, **2016**, Article ID: 3042531. <https://doi.org/10.1155/2016/3042531>
- [31] Zhou, W., Hua, F., Zuo, C., et al. (2016) Primary Uterine Cervical Lymphoma Manifesting as Menolipsis Staged and Followed up by FDG PET/CT. *Clinical Nuclear Medicine*, **41**, 590-593. <https://doi.org/10.1097/RLU.00000000000001196>
- [32] Fratoni, S., Abruzzese, E., Trawinska, M.M., et al. (2016) Primitive "Spindle Cell Variant" (Sarcomatoid Variant) Diffuse Large B-Cell Lymphoma of the Uterine Cervix: Description and Outcome of a Rare Case. *International Journal of Gynecological Pathology: Official Journal of the International Society of Gynecological Pathologists*, **35**, 593-597. <https://doi.org/10.1097/PGP.0000000000000294>
- [33] Singh, L., Madan, R., Benson, R., et al. (2016) Primary Non-Hodgkins Lymphoma of Uterine Cervix: A Case Report of Two Patients. *Journal of Obstetrics and Gynaecology of India*, **66**, 125-127. <https://doi.org/10.1007/s13224-014-0647-8>
- [34] Dobrosavljevic, A., Skrobic, M., Stanojevic, D., et al. (2016) Primary Non-Hodgkin Lymphoma of the Uterine Cervix of a Follicular Type—Case Report. *Journal of Obstetrics and Gynaecology: The Journal of the Institute of Obstetrics and Gynaecology*, **36**, 685-686. <https://doi.org/10.3109/01443615.2016.1148677>
- [35] Omori, M., Oishi, N., Nakazawa, T., et al. (2016) Extranodal NK/T-Cell Lymphoma, Nasal Type of the Uterine Cervix:

- A Case Report. *Diagnostic Cytopathology*, **44**, 430-433. <https://doi.org/10.1002/dc.23439>
- [36] Igwe, E., Diaz, J. and Ferriss, J. (2014) Diffuse Large B Cell Lymphoma of the Cervix with Rectal Involvement. *Gynecologic Oncology Reports*, **10**, 1-4. <https://doi.org/10.1016/j.gore.2014.07.004>
- [37] Li, W.S., Wang, R.C., Wang, J., *et al.* (2015) Primary Nodular Lymphocyte-Predominant Hodgkin Lymphoma of Uterine Cervix Mimicking Leiomyoma. *Clinical Case Reports*, **3**, 349-352. <https://doi.org/10.1002/ccr3.246>
- [38] Wang, G.N., Zhao, W.G., Gao, X.Z., *et al.* (2015) Primary Natural Killer/T Cell Lymphoma of the Cervix: Case Report and Clinicopathological Analysis. *Taiwanese Journal of Obstetrics & Gynecology*, **54**, 71-74. <https://doi.org/10.1016/j.tjog.2014.11.010>
- [39] Mouhajir, N., Diakité, A., Toulba, A., *et al.* (2014) Primary Non-Hodgkin's Lymphoma of the Uterine Cervix: Case Report of Long-Term Survival Patient. *Journal of Obstetrics and Gynaecology of India*, **64**, 145-147. <https://doi.org/10.1007/s13224-013-0483-2>
- [40] Kosari, F., Niknejad, N., Nili, F., *et al.* (2017) Peripheral T-Cell Lymphoma Presenting as a Primary Uterine Cervix Mass: A Report of a Rare Case. *International Journal of Gynecological Pathology: Official Journal of the International Society of Gynecological Pathologists*, **36**, 523-527. <https://doi.org/10.1097/PGP.0000000000000358>
- [41] Mandato, V.D., Palermo, R., Falbo, A., *et al.* (2014) Primary Diffuse Large B-Cell Lymphoma of the Uterus: Case Report and Review. *Anticancer Research*, **34**, 4377-4390.
- [42] Bellevicine, C., Zabatta, A., Malapelle, U., *et al.* (2014) Diffuse Large B-Cell Extranodal Lymphoma of the Uterine Cervix: An Incidental Pap Smear Finding with Histological and Immunohistochemical Correlation. *Diagnostic Cytopathology*, **42**, 644-646. <https://doi.org/10.1002/dc.22966>
- [43] Kosari, F., Daneshbod, Y., Parwaresch, R., *et al.* (2005) Lymphomas of the Female Genital Tract: A Study of 186 Cases and Review of the Literature. *The American Journal of Surgical Pathology*, **29**, 1512-1520. <https://doi.org/10.1097/01.pas.0000178089.77018.a9>
- [44] Weng, X., Huang, M., Zhang, M., *et al.* (2023) Primary Lymphoma of the Uterine Cervix: A Clinicopathologic Study of 13 Cases with Review of Additional 54 Cases in the Literature. *Virchows Archiv: An International Journal of Pathology*, **482**, 419-429. <https://doi.org/10.1007/s00428-022-03436-y>
- [45] Korcum, A.F., Karadogan, I., Aksu, G., *et al.* (2007) Primary Follicular Lymphoma of the Cervix Uteri: A Review. *Annals of Hematology*, **86**, 623-630. <https://doi.org/10.1007/s00277-007-0328-0>
- [46] Nasioudis, D., Kampaktsis, P.N., Frey, M., *et al.* (2017) Primary Lymphoma of the Female Genital Tract: An Analysis of 697 Cases. *Gynecologic Oncology*, **145**, 305-309. <https://doi.org/10.1016/j.ygyno.2017.02.043>
- [47] Tomarchio, V. and Rigacci, L. (2023) FDG-PET in Relapsed/Refractory Hodgkin Lymphoma: A Practical Approach. *Chemotherapy*.
- [48] Korivi, B.R., Jensen, C.T., Patnana, M., *et al.* (2014) A Rare Presentation of Lymphoma of the Cervix with Cross-Sectional Imaging Correlation. *Case Reports in Radiology*, **2014**, Article ID: 157268. <https://doi.org/10.1155/2014/157268>
- [49] Stroh, E.L., Besa, P.C., Cox, J.D., *et al.* (1995) Treatment of Patients with Lymphomas of the Uterus or Cervix with Combination Chemotherapy and Radiation Therapy. *Cancer*, **75**, 2392-2399. [https://doi.org/10.1002/1097-0142\(19950501\)75:9<2392::AID-CNCR2820750932>3.0.CO;2-Y](https://doi.org/10.1002/1097-0142(19950501)75:9<2392::AID-CNCR2820750932>3.0.CO;2-Y)
- [50] Hilal, Z., Hartmann, F., Dogan, A., *et al.* (2016) Lymphoma of the Cervix: Case Report and Review of the Literature. *Anticancer Research*, **36**, 4931-4940. <https://doi.org/10.21873/anticancer.11059>
- [51] Cao, X.X., Li, J., Zhang, W., *et al.* (2014) Patients with Primary Diffuse Large B-Cell Lymphoma of Female Genital Tract Have High Risk of Central Nervous System Relapse. *Annals of Hematology*, **93**, 1001-1005. <https://doi.org/10.1007/s00277-013-2003-y>