

# 1型神经纤维瘤病合并萎缩性腰椎侧凸术后冠状面失代偿的发生率及转归

阚广澳<sup>1</sup>, 陈 虔<sup>1</sup>, 冯轶凡<sup>1</sup>, 陈 杰<sup>1</sup>, 朱泽章<sup>1,2\*</sup>

<sup>1</sup>安徽医科大学附属滁州医院骨科, 安徽 滁州

<sup>2</sup>南京大学医学院附属鼓楼医院脊柱外科, 江苏 南京

收稿日期: 2026年4月26日; 录用日期: 2026年5月21日; 发布日期: 2026年5月27日

## 摘要

目的: 通过1型神经纤维瘤病合并萎缩性腰椎侧凸(Dystrophic lumbar scoliosis secondary to type 1 neurofibromatosis, DLS-NF1)患者的影像学数据, 评估并分析术后冠状面失代偿的发生率及转归。方法: 回顾性分析2007年1月至2018年3月于南京市鼓楼医院接受手术的DLS-NF1患者的病历及影像学资料。根据术前冠状面平衡的鼓楼分型分为3型: A型——术前冠状面平衡距离(Coronal balance distance, CBD)  $\leq 30$  mm, B型——术前CBD  $> 30$  mm且C7铅垂线向凹侧偏移, C型——术前CBD  $> 30$  mm且C7铅垂线向凸侧偏移, 根据术后即刻影像学参数分为冠状面失平衡(coronal imbalanced)组(CIB组)和冠状面平衡(coronal balanced)组(CB组)。记录患者的术前、术后即刻及末次随访时的影像学参数: 包括脊柱Cobb角(主弯、代偿弯), CBD, 远端固定椎(Lowest Instrumented Vertebra, LIV), 远端代偿椎间盘数目, 并记录其冠状面形态的变化情况。结果: 本研究共纳入39例DLS-NF1患者, 其中26例(66.7%)男性, 13例(33.3%)女性。平均随访时间为 $34.1 \pm 26.2$ 个月。术前冠状面平衡(鼓楼A型)患者22例(56.4%), 术前冠状面失平衡(鼓楼C型)患者17例(43.6%)。术后即刻CIB组23例(59.0%), CB组16例(41.0%), 两组术前主弯角度分别为CIB组 $57.3^\circ \pm 19.7^\circ$ 和CB组 $62.3^\circ \pm 16.9^\circ$ , 术后分别矫正至 $20.5^\circ \pm 12.1^\circ$ 和 $26.0^\circ \pm 19.5^\circ$ , 末次随访时分别为 $22.2^\circ \pm 12.5^\circ$ 和 $29.4^\circ \pm 20.3^\circ$ 。术后矫正率分别为 $65.1\% \pm 13.8\%$ 和 $61.6\% \pm 22.9\%$ 。13.04% (3例)的CIB组患者远端代偿椎间盘数目  $\geq 2$ 个, CB组中则为68.75% (11例), 两组间差异有统计学意义( $P < 0.001$ ); 在远端椎间盘代偿数量  $< 2$ 的组别中, CIB组共有20例, CB组则为5例, 两组间差异有统计学意义( $P < 0.001$ )。两组术前CBD分别为 $(24.7 \pm 19.5)$  mm和 $(21.3 \pm 16.8)$  mm, 术后为 $(41.6 \pm 10.8)$  mm和 $(13.3 \pm 11.1)$  mm, 差异有统计学意义( $P < 0.001$ )。术前分型为冠状面平衡组的患者中有9例术后早期出现冠状面失平衡, 而术前鼓楼C型患者中有14例术后早期仍保持冠状面失平衡, 差异有统计学意义( $P = 0.020$ )。在末次随访时, 共有37例(94.8%)鼓楼A型患者, 1例(2.5%)鼓楼B型患者及1例(2.5%)鼓楼C型患者。结论: DLS-NF1患者术后早期冠状面失代偿发生率较高(59.0%), 主要受术前鼓楼C型冠状面失平衡、主弯矫正率偏高及远端代偿椎间盘不足(LIV延伸至L3以下)驱动, 但绝大多数患者在远期随访中最终能通过自发重塑获得满意的冠状面平衡与临床结局。

## 关键词

神经纤维瘤病1型, 萎缩性侧凸, 脊柱矫形手术, 冠状面失代偿, 临床转归

\*通讯作者。

文章引用: 阚广澳, 陈虔, 冯轶凡, 陈杰, 朱泽章. 1型神经纤维瘤病合并萎缩性腰椎侧凸术后冠状面失代偿的发生率及转归[J]. 临床医学进展, 2026, 16(5): 2650-2659. DOI: 10.12677/acm.2026.1652075

# Postoperative Coronal Imbalance in Dystrophic Lumbar Scoliosis Secondary to Neurofibromatosis Type 1: Incidence and Outcomes

Guang'ao Kan<sup>1</sup>, Qian Chen<sup>1</sup>, Yifan Feng<sup>1</sup>, Jie Chen<sup>1</sup>, Zezhang Zhu<sup>1,2\*</sup>

<sup>1</sup>Department of Orthopedics, Chuzhou Hospital Affiliated to Anhui Medical University, Chuzhou Anhui

<sup>2</sup>Department of Orthopedic Spine Surgery, Drum Tower Hospital Affiliated to Medical School of Nanjing University, Nanjing Jiangsu

Received: April 26, 2026; accepted: May 21, 2026; published: May 27, 2026

## Abstract

**Objective:** Through the imaging data of patients with dystrophic lumbar scoliosis secondary to type 1 neurofibromatosis (DLS-NF1), the incidence and outcome of postoperative coronal decompensation were evaluated and analyzed. **Methods:** The medical records and imaging data of patients with DLS-NF1 who underwent surgery in Nanjing Drum Tower Hospital from January 2007 to March 2018 were retrospectively analyzed. According to the drum tower classification of preoperative coronal balance, it was divided into three types: type A—preoperative coronal balance distance (CBD)  $\leq 30$  mm, type B—preoperative CBD  $> 30$  mm and C7 plumb line shifted to the concave side, type C—preoperative CBD  $> 30$  mm and C7 plumb line shifted to the convex side. According to the immediate postoperative imaging parameters, it was divided into coronal imbalance group (CIB group) and coronal balance group (CB group). The preoperative, immediate postoperative and final follow-up imaging parameters of the patients were recorded, including the Cobb angle of the spine (main curve, compensatory curve), CBD, Lowest Instrumented Vertebra (LIV), the number of distal compensatory intervertebral discs, and the changes of coronal morphology. **Results:** A total of 39 patients with DLS-NF1 were included in this study, including 26 males (66.7%) and 13 females (33.3%). The mean follow-up time was  $34.1 \pm 26.2$  months. There were 22 patients (56.4%) with preoperative coronal balance (type A) and 17 patients (43.6%) with preoperative coronal imbalance (type C). Immediately after operation, there were 23 cases (59.0%) in CIB group and 16 cases (41.0%) in CB group. The preoperative main curve angles of the two groups were  $57.3^\circ \pm 19.7^\circ$  in CIB group and  $62.3^\circ \pm 16.9^\circ$  in CB group, which were corrected to  $20.5^\circ \pm 12.1^\circ$  and  $26.0^\circ \pm 19.5^\circ$  after operation, and  $22.2^\circ \pm 12.5^\circ$  and  $29.4^\circ \pm 20.3^\circ$  at the last follow-up. The postoperative correction rates were  $65.1\% \pm 13.8\%$  and  $61.6\% \pm 22.9\%$  respectively. 13.04% (3 cases) of the CIB group had more than 2 distal compensatory intervertebral discs, and 68.75% (11 cases) of the CB group, the difference between the two groups was statistically significant ( $P < 0.001$ ); in the group with distal disc compensation  $< 2$ , there were 20 cases in CIB group and 5 cases in CB group, the difference between the two groups was statistically significant ( $P < 0.001$ ). The preoperative CBD of the two groups was  $(24.7 \pm 19.5)$  mm and  $(21.3 \pm 16.8)$  mm, respectively, and the postoperative CBD was  $(41.6 \pm 10.8)$  mm and  $(13.3 \pm 11.1)$  mm, respectively, the difference was statistically significant ( $P < 0.001$ ). There were 9 patients with coronal imbalance in the preoperative classification of coronal balance group, while 14 patients with preoperative tympanic floor type C still maintained coronal imbalance in the early postoperative period, and the difference was statistically significant ( $P = 0.020$ ). At the last follow-up, there were 37 patients (94.8%) with type A, 1 patient (2.5%) with type B and 1 patient (2.5%) with type C of the Drum Tower. **Conclusion:** The incidence of early postoperative coronal decompensation in patients with DLS-NF1 was high (59.0%), which was

mainly driven by preoperative tympanic type C coronal imbalance, the correction rate of the main bend is high and insufficient distal compensatory disc (LIV extended below L3), but most patients could finally obtain satisfactory coronal balance and clinical outcome through spontaneous remodeling during long-term follow-up.

## Keywords

Neurofibromatosis Type 1, Dystrophic Scoliosis, Spinal Osteotomy and Fusion Surgery, Coronal Imbalance, Clinical Outcome

Copyright © 2026 by author(s) and Hans Publishers Inc.

This work is licensed under the Creative Commons Attribution International License (CC BY 4.0).

<http://creativecommons.org/licenses/by/4.0/>



Open Access

## 1. 引言

1 型神经纤维瘤病(Type 1 Neurofibromatosis, NF1)是一种常染色体显性遗传性疾病, 发病率为 1/3000~1/3500 [1] [2], 当其骨骼系统受累时会表现为脊柱侧弯, 侧弯通常表现为短节段、成角锐利的“营养不良性”侧凸, 即萎缩性侧凸, 并常伴有椎体、肋骨、椎弓根等结构的严重萎缩、旋转和扇贝样改变, 从而破坏脊柱的稳定性[3]。因此, 手术干预是阻止此类畸形进展、改善躯干平衡和预防神经功能损害的主要手段[4]。然而, 1 型神经纤维瘤病伴萎缩性腰椎侧凸(Dystrophic lumbar scoliosis secondary to type 1 neurofibromatosis, DLS-NF1)的矫形手术存在极大的术后并发症风险[5]。其中, 术后冠状面失代偿是后果尤为严重的并发症之一, 临床表现为躯干倾斜、骨盆倾斜、双肩不等高, 严重者可导致步态异常、顽固性腰背疼痛, 严重影响患者生活质量[6] [7]。DLS-NF1 有其独特的曲线特征, 部分患者表现为尖角和后凸, 甚至会出现腰椎局限性旋转半脱位(Vertebral Rotating Subluxation, VRS)的双弯。此外, 类似退变性腰椎侧凸的冠状面失平衡的发生率也较高[8]-[10], 在青少年特发性脊柱侧凸(Adolescent Idiopathic Scoliosis, AIS)(如 Lenke 5C 型)和退变性腰椎侧凸的研究中, 已有相关研究证实了术前冠状面分型、椎旁肌退变以及远端固定椎(Lowest Instrumented Vertebra, LIV)的选择会影响冠状面平衡[11]-[14]。同时, 既往文献对 NF1 伴萎缩性脊柱侧凸的冠状面平衡的探讨, 大部分研究主要局限于胸段侧凸[15] [16], 但对于腰段侧凸的研究较少。

尽管脊柱内固定技术与矫形策略已取得显著进展, 但 NF1 患者术后冠状面失代偿的发生仍是一个多因素驱动的复杂病理过程。因此, 本研究旨在通过回顾性分析 39 例 DLS-NF1 患者术前术后影像学参数, 预测此类患者术后冠状面失代偿的发生率, 并从多角度探讨其潜在机制与远期临床转归。本研究结果将为术前精准评估与手术策略的优化提供循证依据, 对降低术后并发症风险、改善患者远期预后具有重要的临床价值。

## 2. 资料与方法

### 2.1. 纳入标准与排除标准

纳入标准: ① 明确诊断为 NF1; ② 伴有腰椎侧凸畸形(主弯为腰弯); ③ 具备完整的临床及影像学资料; ④ 术后影像学随访时间不少于 2 年; ⑤ 接受后路或前路联合手术治疗。

排除标准: ① 颈椎后凸畸形; ② 生长棒治疗; ③ 双下肢不等长; ④ 合并术前神经功能损害, 无法评估直立位时的冠状位和矢状位序列; ⑤ 既往脊柱手术史。

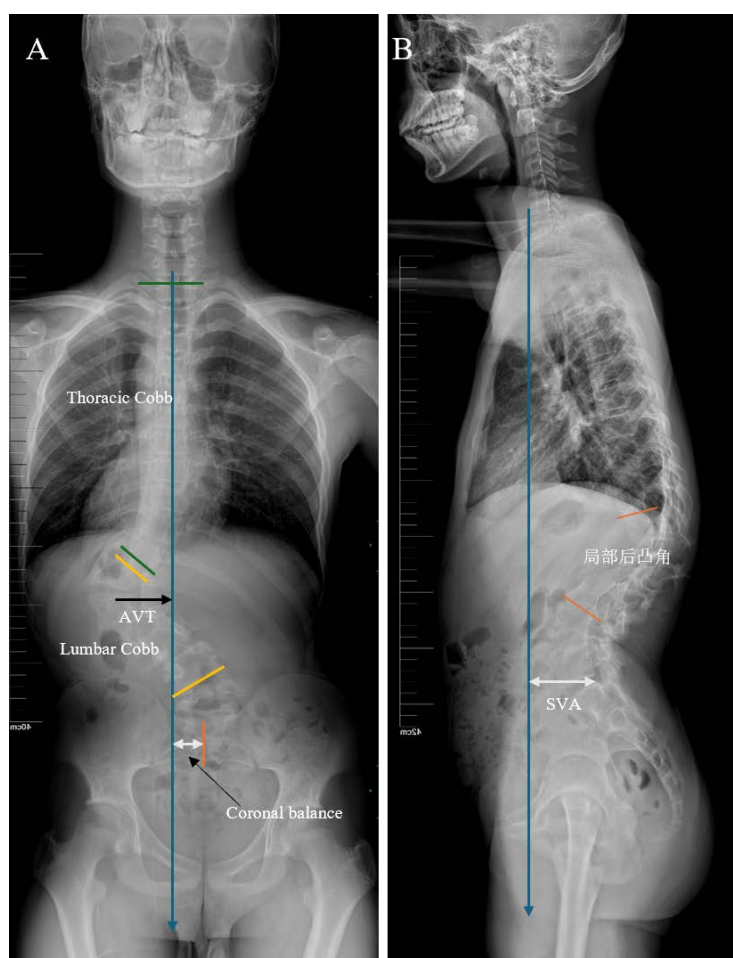
## 2.2. 一般资料

选取 2007 年 1 月至 2018 年 3 月于南京市鼓楼医院收治 DLS-NF1 患者 62 例, 满足纳排标准 39 例, 根据术前冠状面平衡的鼓楼分型进行分型[17], A 型( $CBD \leq 30$  mm) 22 (56.4%)例, B 型( $CBD > 30$  mm 且 C7 铅垂线向凹侧偏移) 0 例, C 型( $CBD > 30$  mm 且 C7 铅垂线向凸侧偏移) 17 (43.6%)例。根据术后即刻 X 光片, 将发生冠状面失平衡的患者分为冠状面失平衡组(coronal imbalanced group, CIB 组): 23 例(59.0%)、冠状面平衡组(coronal balanced group, CB 组): 16 例(41.0%)。

## 2.3. 观察指标

主要观察指标为术前、术后、末次随访站立位全脊柱正、侧位 X 线片的影像学参数。

### 影像学资料



**Figure 1.** (A) Coronal imaging parameters; (B) Sagittal imaging parameters

**图 1.** (A) 冠状面影像学参数; (B) 矢状面影像学参数

腰弯 Cobb 角: 站立位全脊柱正位 X 线片上, 选取腰弯的上端椎(最倾斜的椎体上方)和下端椎(最倾斜的椎体下方), 分别作其上下终板的垂线, 两垂线夹角即为腰弯 Cobb 角(见图 1(A))。

胸弯 Cobb 角: 站立位全脊柱正位 X 线片上, 选取胸弯的上端椎(最倾斜的椎体上方)和下端椎(最倾斜的椎体下方), 分别作其上下终板的垂线, 两垂线夹角即为胸弯 Cobb 角(见图 1(A))。

CBD: 即为 C7 铅垂线(C7 plumb line, C7PL)至骶骨中垂线(center sacral vertical line, CSVL)的水平距离, 当偏移距离超过 30 mm 时即为冠状面失平衡, 反映冠状面平衡的状态(见图 1(A))。

顶椎偏移距离(Apical Vertebral Translation, AVT): 站立位全脊柱正位 X 线片上腰椎侧凸顶椎(主弯角度最大处的椎体)中点至骶骨中垂线的水平垂直距离(见图 1(A))。

矢状面垂直距离(Sagittal Vertical Axis, SVA): 站立位全脊柱侧位 X 线片上 C7 铅垂线与 S1 后上角的水平距离。当 SVA 前或后超过 30 mm 时即为失平衡。C7 铅垂线位于 S1 后上缘前方为正值, 反之则为负值(见图 1(B))。

### 2.4. 统计学分析

本研究采用 SPSS 29.0 软件(IBM 公司)进行数据分析。采用配对样本 t 检验比较各组手术变化情况, 计量资料采用配对样本 t 检验比较各组手术变化情况。此外, 根据所分析变量的参数质量, 使用 Student t 检验、卡方检验、Fisher 精确检验和 Wilcoxon 符号秩检验对数据进行组间比较。任意 P 值 < 0.05 为差异有统计学意义。

### 3. 结果

**Table 1.** General data and clinical characteristics of NF1 patients with atrophic lumbar curvature

**表 1.** NF1 伴萎缩性腰弯患者一般资料和临床特征

	CIB 组(n = 23)	CB 组(n = 16)	P 值
性别(女/男)	8/15	5/11	1.000
年龄(岁)	14.8 ± 4.2	14.3 ± 2.2	0.480
萎缩性节段数	4.1 ± 1.0	4.3 ± 1.0	0.574
远端代偿椎间盘数			<b>0.001</b>
2 个及以上	3	11	
2 个以下	20	5	
融合节段数	8.5 ± 2	8.8 ± 2	0.710
手术入路			1.000
单纯后路	18	13	
前后路联合	5	3	
随访时间(月)	33.8 ± 27.8	34.3 ± 24.3	0.957

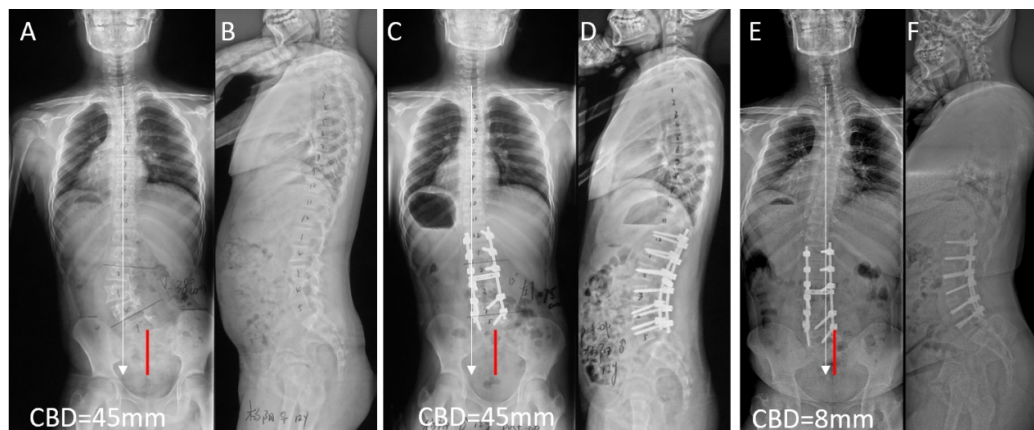
**Table 2.** Comparison of imaging parameters before and after surgery and follow-up between the two groups

**表 2.** 两组患者手术前后及随访的影像学参数比较

	CIB 组(n = 23)	CB 组(n = 16)	P 值
主弯 Cobb 角(°)			
术前	57.3 ± 19.7	62.3 ± 16.9	0.457
术后	20.5 ± 12.1	26.0 ± 19.5	0.329
末次随访	22.2 ± 12.5	29.4 ± 20.3	0.215
矫正率(%)	65.1 ± 13.8	61.6 ± 22.9	0.348
矫正丢失(%)	4.0 ± 3.2	5.6 ± 3.3	0.191

续表

CB (mm)			
术前	24.7 ± 19.5	21.3 ± 16.8	0.616
术后	41.6 ± 10.8	13.3 ± 11.1	<0.001
末次随访	7.9 ± 12.8	-2.5 ± 19.1	0.070
顶椎偏移距离(mm)			
术前	52.1 ± 18.2	57.4 ± 18.2	0.417
术后	32.2 ± 16.5	21.8 ± 16.6	0.089
末次随访	20.5 ± 15.2	21.5 ± 17.3	0.868
胸弯 Cobb 角(°)			
术前	5.1 ± 9.7	10.7 ± 8.3	0.101
术后	1.9 ± 6.8	1.6 ± 7.6	0.910
末次随访	1.1 ± 10.9	-0.6 ± 10.0	0.645
SVA (mm)			
术前	-20.3 ± 23.3	-23 ± 22	0.739
术后	-23.1 ± 28.6	-18.4 ± 35.1	0.680
末次随访	-10.5 ± 20.6	-14.9 ± 27.0	0.599

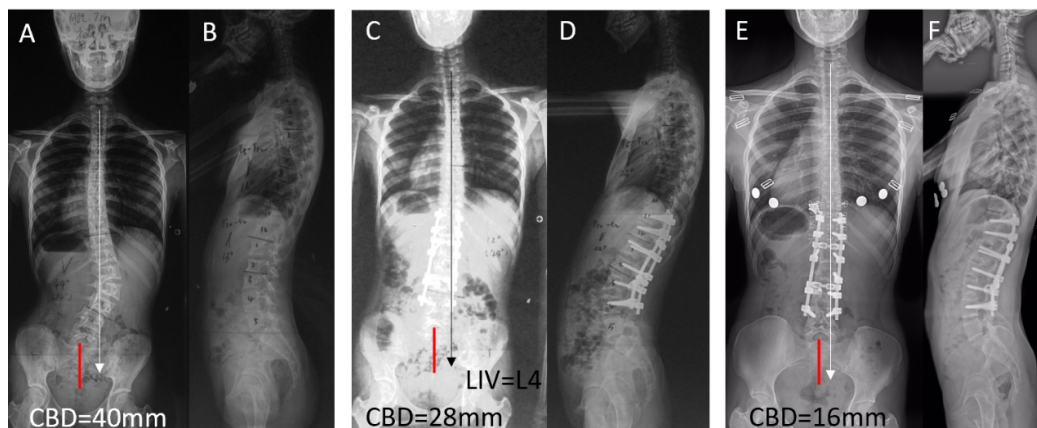


**Figure 2.** The patient was a 12-year-old male. Imaging evolution of coronal decompensation after posterior osteotomy and internal fixation

**图 2.** 患者为 12 岁男性。行后路截骨矫形内固定术后出现冠状面失代偿的影像学演变

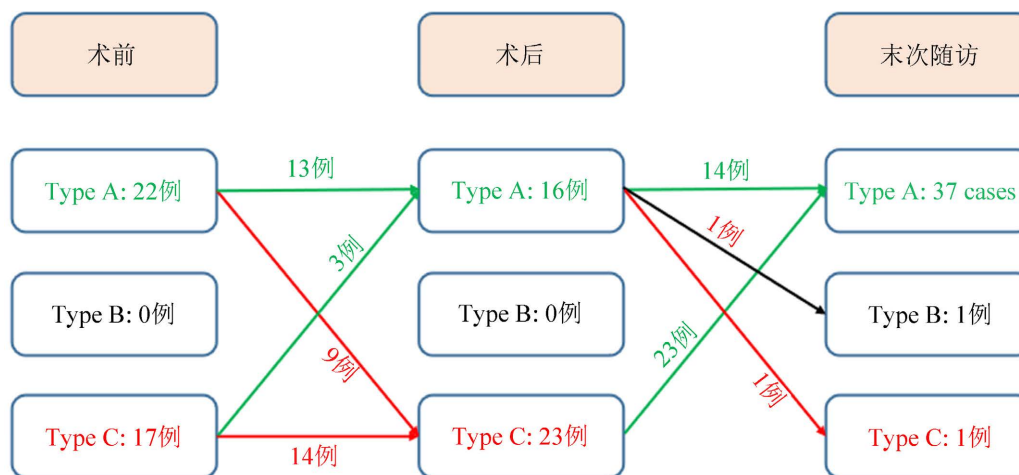
术前站立位全脊柱正侧位 X 线片(A、B)：严重的短节段萎缩性腰椎侧凸，术后即刻正侧位 X 线片(C、D)：主弯获得矫正，但出现明显的医源性冠状面失代偿，冠状面平衡距离(CBD)为 45 mm。术后长期随访正侧位 X 线片(E、F)：患者通过远端未融合节段及躯干肌肉的代偿重塑，冠状面失平衡获得显著改善，CBD 恢复至 8 mm，实现了整体冠状面的重新平衡(图 2)。

术前立位全脊柱正侧位 X 线片(A、B)：严重的腰椎侧凸畸形，术前冠状面平衡距离(CBD)为 40 mm。术后即刻正侧位 X 线片(C、D)：主弯获得良好矫正，LIV 选择于 L4，由于主弯矫正后的应力改变，术后早期冠状面恢复了平衡，CBD 为 28 mm。末次随访时的正侧位 X 线片(E、F)：患者通过远端未融合椎间盘(L4~S1)的代偿作用，冠状面序列获得显著重塑，整体冠状面平衡得到明显改善，CBD 缩小至 16 mm(图 3)。



**Figure 3.** The patient was a 13-year-old female who underwent coronal imaging evolution after posterior spinal fusion

**图 3.** 患者为 13 岁女性，行后路脊柱矫形融合术后冠状面的影像学演变



**Figure 4.** The distribution of coronal balance classification before and after operation and follow-up, and the change of coronal balance classification after operation.

**图 4.** 患者手术前后及随访冠状面平衡分型的分布情况，以及术后冠状面平衡分型的转变

### 手术情况

39 例患者中 31 例患者接受了单纯后路手术，8 例患者接受了前后路联合手术，均顺利完成手术。根据术后即刻出现是否出现冠状面不平衡分为冠状面不平衡组(coronal imbalanced group, CIB 组): 23 例 (59.0%)，冠状面平衡组(coronal balanced group, CB 组): 16 例(41.0%)。CIB 组和 CB 组手术时平均年龄分别为  $14.8 \pm 4.2$  岁和  $14.3 \pm 2.2$  岁。CIB 组顶椎分布情况为 L1 (7 例)、L2 (10 例)、L3 (4 例)和 L4 (2 例)，CB 组顶椎分布则是 L1 (6 例)、L2 (5 例)、L3 (3 例)及 L4 (2 例)。CIB 组有 14 例存在实体瘤，而 CB 组有 11 例。只有 CIB 组出现 2 例腰椎局限性双弯，其余均为单一腰弯。两组患者均得到了 2 年以上的随访时间，平均随访时间分别为( $33.8 \pm 27.8$ )月和( $34.3 \pm 24.3$ )月(表 1)。

术前，CIB 组与 CB 组在腰弯 Cobb 角( $57.3^\circ \pm 19.7^\circ$  vs.  $62.3^\circ \pm 16.9^\circ$ )、顶椎偏移距离( $52.1 \pm 18.2$  mm vs.  $57.4 \pm 18.2$  mm)、SVA ( $-20.3 \pm 23.3$  mm vs.  $-23 \pm 22$  mm)及 CBD ( $24.7 \pm 19.5$  mm vs.  $21.3 \pm 16.8$  mm)等参数方面的差异均  $P > 0.05$ 。术后及末次随访时，两组患者的各项影像学参数均得到改善。其中，CIB 组与 CB 组术后腰弯 Cobb 角分别矫正至  $20.5^\circ \pm 12.1^\circ$  和  $26.0^\circ \pm 19.5^\circ$  (末次随访分别为  $22.2^\circ \pm 12.5^\circ$  和  $29.4^\circ$ )。

$\pm 20.3^\circ$ ); CIB 组主弯矫正率为  $65.1\% \pm 13.8\%$ , 在数值上略高于 CB 组的  $61.6\% \pm 22.9\%$ , 但组间差异  $P > 0.05$ 。两组术后( $32.2 \pm 16.5 \text{ mm}$  vs.  $21.8 \pm 16.6 \text{ mm}$ )及末次随访时( $20.5 \pm 15.2 \text{ mm}$  vs.  $21.5 \pm 17.3 \text{ mm}$ )的顶椎偏移距离, 以及术后和末次随访的 SVA 组间比较, 亦均未见显著差异(均  $P > 0.05$ )。值得注意的是, 术后即刻 CIB 组的 CBD ( $41.6 \pm 10.8 \text{ mm}$ )显著大于 CB 组( $13.3 \pm 11.1 \text{ mm}$ ,  $P < 0.001$ ), 但至末次随访时两组的 CBD 分别恢复至  $7.9 \pm 12.8 \text{ mm}$  和  $2.5 \pm 19.1 \text{ mm}$ , 组间差异无统计学意义( $P > 0.05$ )。此外, 在远端代偿椎间盘数量方面, CIB 组绝大多数患者为 2 个以下(20 人, 2 个及以上仅 3 人), 而 CB 组则以 2 个及以上为主(11 人, 2 个及以下 5 人), 两组间分布差异具有统计学意义( $P < 0.001$ ) (表 1, 表 2)。

## 4. 讨论

目前大多数研究主要探究术后即刻冠状面失衡 CS 患者随访过程中的转归, 但少有针对 DLS-NF1 的术后冠状面失代偿的研究。本文通过比较 DLS-NF1 患者术前、术后即刻以及末次随访的相关影像学参数, 探究与术后冠状面失衡相关的因素, 探索可能与预后相关的手术因素。

### 4.1. DLS-NF1 术后冠状面失代偿的发生率

AIS、退变性脊柱侧凸患者在接受脊柱矫形手术后, 往往会面临着发生术后冠状面失衡等并发症的可能。本研究结果显示术前有 43.6% (17/39) 的患者表现为鼓楼 C 型冠状面失代偿, 术后即刻出现冠状面失代偿的发生率为 59.0% (23/39) (均为鼓楼 C 型冠状面失代偿), 显著高于 Lenke 5C AIS (31.5%~46.3%) [15] [16]。XU 等[10]在一项针对 130 名胸腰段先天性脊柱侧凸患者中有 26 (20.0%) 例术后出现冠状面失衡, 也显著低于本研究中 DLS-NF1 患者。

### 4.2. DLS-NF1 术后冠状面失代偿的机制

DLS-NF1 患者往往表现为短节段、锐角且极其僵硬的畸形。若术中盲目追求主弯(如胸腰段)的完美解剖复位和过大矫正率, 而未被融合的下腰椎或腰骶段由于局部软组织挛缩或骨发育不良无法提供足够的代偿, 就会导致躯干重心向一侧偏移, 本研究数据表明 CIB 组中主弯矫正率( $65.1\% \pm 13.8\%$ )高于 CB 组中主弯矫正率( $61.6\% \pm 22.9\%$ ), 表明主弯矫正率偏高可能与该类患者出现术后冠状面失代偿相关。

融合节段的选择对脊柱侧凸矫形术的成功至关重要。融合节段过短可能导致残留畸形加重, 引发冠状面失代偿; 而融合节段过长则会限制脊柱的运动, 增加邻近节段的退变风险, 同时由于融合节段的不当选择也可能导致新的力学失衡。脊柱融合术中尽可能保留远端运动节段能够维持腰椎远端活动度, 同时也保留了患者冠状面及矢状面平衡的代偿能力[18]-[20]。本研究发现在 CIB 组中远端代偿椎间盘数目 2 个以下为 20/23 (87.0%) 例, 而 CB 组中则为 5/16 (31.3%) ( $P < 0.001$ , 差异有统计学意义)。因此, 远端代偿椎间盘数目的不足(LIV 选择在 L3 以下), 也可能是导致该类患者发生术后冠状面失代偿的危险因素。

Bao 等[17]在 2016 年的一项研究中显示退变性腰椎侧凸患者中术前鼓楼 C 型患者占 14.5%, 其中有 60.0% 患者术后出现冠状面失代偿, 而本研究显示 DLS-NF1 术前鼓楼 C 型患者中 82.4% (14/17) 在术后即刻出现冠状面失代偿, 可见, 二者均存在较高的术后冠状面失代偿发生率, 但与退变性患者相比, DLS-NF1 患者发生率更高。因此, 术前鼓楼 C 型冠状面失代偿是此类患者术后即刻出现冠状面失代偿的危险因素之一。在一项纳入 120 例 AIS 患者的回顾性研究中, 术前冠状面分型为鼓楼 C 型失代偿患者占比为 52.5%, 其中 38.0% 术后即刻出现冠状面失代偿, 远低于 DLS-NF1 术前鼓楼 C 型冠状面失代偿患者的 82.4% [21]。这可能与 DLS-NF1 的特殊解剖结构相关[3] [22] [23]。

### 4.3. DLS-NF1 术后冠状面失代偿的转归

在本研究中所纳入的患者中, 所有 DLS-NF1 术后出现鼓楼 C 型 53% (23/39) 的患者在长期的随访中,

大部分能获得冠状面的平衡 94.9% (37/39) (见图 4), 该比例显著高于文献报道的其他类型脊柱侧凸患者: 腰椎 AIS 患者为 85.7% (6/7) [10], 退变性腰椎侧凸为 57.7% (15/26) [24], 胸腰段/腰段先天性脊柱侧凸为 26.1% (6/23) [14], 这可能与患者相对年轻, 远端椎间盘数目较多及近端胸弯代偿有关。一方面, 由于融合节段没有至骨盆, 因此有一定数量的可以活动的椎间盘, 具有相应的代偿能力; 另一方面, 由于融合节段之上有许多未被固定的胸椎节段, 可以产生代偿弯以恢复冠状面平衡。因此, 即使 DLS-NF1 患者术后早期出现冠状面失代偿的几率较大, 但是大部分患者在随访过程中会获得良好的冠状面平衡。

## 5. 本研究局限性

本研究所选取的病例均由南京鼓楼医院脊柱外科完成手术及随访, 病例数量相对较少, 可能存在数据的偏倚以及手术策略选择的单一。在进一步的研究中, 需要扩大病例数量以及不同中心病例, 以提高数据的准确性和可靠性。缺乏对患者术后与末次随访之间的多次随访, 以及随访时间期待持续延长, 对失代偿机制以及转归进一步验证。

## 6. 结论

综上所述, DLS-NF1 患者术后早期冠状面失代偿的发生率较高。这一高发生率主要归因于以下三大危险因素: 首先, 术前鼓楼 C 型冠状面失衡的比例较高, 术前与术后的失衡状态表现出极强的相关性; 其次, 术中对主弯的矫正率偏高打破了原有的力学代偿; 最后, 远端保留的可用于代偿的活动椎间盘数量不足(LIV 延伸至 L3 以下), 严重限制了术后的脊柱形态代偿能力。然而, 在长期随访中, 大多数早期术后冠状面失代偿的患者最终都能实现令人满意的冠状面平衡和良好的临床结局。

## 声明

本研究获得南京市鼓楼医伦理委员会批准(审批号: 2021-398-01)。

## 参考文献

- [1] Boyd, K.P., Korf, B.R. and Theos, A. (2009) Neurofibromatosis Type 1. *Journal of the American Academy of Dermatology*, **61**, 1-14. <https://doi.org/10.1016/j.jaad.2008.12.051>
- [2] Almuqbil, M., Alshaikh, F., Altwaijri, W., Baarmah, D., Hommady, R., Alshaikh, M., et al. (2024) Epidemiology and Outcomes of Neurofibromatosis Type 1 (NF-1): Multicenter Tertiary Experience. *Journal of Multidisciplinary Healthcare*, **17**, 1303-1314. <https://doi.org/10.2147/jmdh.s454921>
- [3] Toro, G., Santoro, C., Ambrosio, D., Landi, G., Scilipoti, M., Moretti, A., et al. (2021) Natural History of Scoliosis in Children with NF1: An Observation Study. *Healthcare*, **9**, Article 881. <https://doi.org/10.3390/healthcare9070881>
- [4] Li, Q., Wang, L., Yang, H., Yang, X., Liu, L., Wang, L., et al. (2024) Surgical Treatment Outcomes of Anterior-Only Correction and Reconstruction for Severe Cervical Kyphotic Deformity with Neurofibromatosis-1: A Retrospective Study with a 5-Year Follow-Up. *Orthopaedic Surgery*, **16**, 1631-1641. <https://doi.org/10.1111/os.14096>
- [5] Wang, D., Zhang, B., Wen, X., Chen, K., Xiao, H., Xu, X., et al. (2024) Clinical Features and Surgical Treatments of Scoliosis in Neurofibromatosis Type 1: A Systemic Review and Meta-Analysis. *European Spine Journal*, **33**, 2646-2665. <https://doi.org/10.1007/s00586-024-08194-w>
- [6] Quan, H., Chengzhen, L., Qixin, C., Yuanqing, S. and Fangcai, L. (2025) Paravertebral Muscle Degeneration Affects Coronal Balance in Patients with Degenerative Lumbar Scoliosis. *World Neurosurgery*, **195**, Article ID: 123644. <https://doi.org/10.1016/j.wneu.2024.123644>
- [7] Wang, D., Zhang, Y., Sima, S., Fan, Z., Zhu, W., Chen, X., et al. (2026) Risk Factors for Postoperative Coronal Malalignment in Degenerative Lumbar Scoliosis and Its Impact on Clinical Outcomes: A Systematic Review and Meta-Analysis. *Spine*, **51**, 143-151. <https://doi.org/10.1097/brs.0000000000005429>
- [8] Yang, C., Zhao, Y., Zhai, X., Li, J., Zhu, X. and Li, M. (2017) Coronal Balance in Idiopathic Scoliosis: A Radiological Study after Posterior Fusion of Thoracolumbar/lumbar Curves (Lenke 5 or 6). *European Spine Journal*, **26**, 1775-1781. <https://doi.org/10.1007/s00586-016-4844-2>
- [9] Mannem, A., Cheung, P.W.H., Kawasaki, S., Shigematsu, H. and Cheung, J.P.Y. (2021) What Determines Immediate

- Postoperative Coronal Balance and Delayed Global Coronal Balance after Anterior Spinal Fusion for Lenke 5C Curves? *European Spine Journal*, **30**, 2007-2019. <https://doi.org/10.1007/s00586-021-06807-2>
- [10] Xu, L., Chen, X., Qiao, J., Chen, Z., Shi, B., Li, S., *et al.* (2019) Coronal Imbalance after Three-Column Osteotomy in Thoracolumbar Congenital Kyphoscoliosis: Incidence and Risk Factors. *Spine*, **44**, E99-E106. <https://doi.org/10.1097/brs.0000000000002773>
- [11] 刘臻, 郭惊, 朱泽章, 等. Lenke5C 型脊柱侧凸后路选择性矫形术下端融合椎影像学改变对冠状面平衡的影响[J]. 中国脊柱脊髓杂志, 2013, 23(12): 1063-1067.
- [12] Li, Z., Du, Y., Zhao, Y., Lin, G., Zhang, H., Li, C., *et al.* (2023) Lowest Instrumented Vertebra at L3 versus L4 in Posterior Fusion for Moderate Lenke 5C Type Adolescent Idiopathic Scoliosis: A Case-Match Radiological Study. *Neurospine*, **20**, 1380-1388. <https://doi.org/10.14245/ns.2346822.411>
- [13] Li, S., Chen, Z., Qiu, Y., Xu, L., Chen, X., Du, C., *et al.* (2018) Coronal Decompensation after Posterior-Only Thoracolumbar Hemivertebra Resection and Short Fusion in Young Children with Congenital Scoliosis. *Spine*, **43**, 654-660. <https://doi.org/10.1097/brs.0000000000002383>
- [14] Liu, Z., Guo, J., Zhu, Z., Qian, B., Sun, X., Xu, L., *et al.* (2013) Role of the Upper and Lowest Instrumented Vertebrae in Predicting the Postoperative Coronal Balance in Lenke 5C Patients after Selective Posterior Fusion. *European Spine Journal*, **22**, 2392-2398. <https://doi.org/10.1007/s00586-013-2808-3>
- [15] Yao, Z., Guo, D., Li, H., Bai, Y., Sun, B., Zhang, X., *et al.* (2019) Surgical Treatment of Dystrophic Scoliosis in Neurofibromatosis Type 1: Outcomes and Complications. *Clinical Spine Surgery: A Spine Publication*, **32**, E50-E55. <https://doi.org/10.1097/bsd.0000000000000716>
- [16] 马彦宇, 毛赛虎, 李松, 等. I型神经纤维瘤病伴萎缩性上胸段脊柱侧凸的冠状面影像学分型[J]. 中国脊柱脊髓杂志, 2024, 34(7): 679-686.
- [17] Bao, H., Yan, P., Qiu, Y., Liu, Z. and Zhu, F. (2016) Coronal Imbalance in Degenerative Lumbar Scoliosis: Prevalence and Influence on Surgical Decision-Making for Spinal Osteotomy. *The Bone & Joint Journal*, **98**, 1227-1233. <https://doi.org/10.1302/0301-620x.98b9.37273>
- [18] Kumar, R.P., Adida, S., Lavadi, R.S., Mitha, R., Legarreta, A.D., Hudson, J.S., *et al.* (2024) A Guide to Selecting Upper Thoracic versus Lower Thoracic Uppermost Instrumented Vertebra in Adult Spinal Deformity Correction. *European Spine Journal*, **33**, 2742-2750. <https://doi.org/10.1007/s00586-024-08206-9>
- [19] Wang, Y., Bünger, C.E., Zhang, Y., Wu, C., Li, H., Dahl, B., *et al.* (2013) Lowest Instrumented Vertebra Selection for Lenke 5C Scoliosis: A Minimum 2-Year Radiographical Follow-Up. *Spine*, **38**, E894-E900. <https://doi.org/10.1097/brs.0b013e31829537be>
- [20] Qin, X., He, Z., Yin, R., Qiu, Y. and Zhu, Z. (2019) Where to Stop Distally in Lenke Modifier C AIS with Lumbar Curve More than 60°: L3 or L4? *Clinical Neurology and Neurosurgery*, **178**, 77-81. <https://doi.org/10.1016/j.clineuro.2019.02.005>
- [21] Fang, Y., Li, J., Hu, Z., Zhu, Z., Qiu, Y. and Liu, Z. (2024) Postoperative Coronal Imbalance in Lenke 5C Adolescent Idiopathic Scoliosis: Evolution, Risk Factors, and Clinical Implications. *Neurospine*, **21**, 903-912. <https://doi.org/10.14245/ns.2448544.272>
- [22] Estefan, M.M., Camino-Willhuber, G., Bosio, S.T., Puigdevall, M. and Maenza, R.A. (2022) Management of NF-1 Dystrophic Scoliosis Associated with Rib Heads Dislocation into the Spinal Canal in Neurological Intact Patients: A Systematic Literature Review. *Spine Deformity*, **10**, 285-294. <https://doi.org/10.1007/s43390-021-00422-3>
- [23] Li, S., Mao, S., Ma, Y., Shi, B., Liu, Z., Zhu, Z., *et al.* (2022) Could Screw/Hook Insertion at the Apical Vertebrae with Rib Head Dislocation Effectively Retract the Corresponding Rib Head from Spinal Canal in Dystrophic Scoliosis Secondary to Type 1 Neurofibromatosis? *BMC Musculoskeletal Disorders*, **23**, Article No. 285. <https://doi.org/10.1186/s12891-022-05248-2>
- [24] Bao, H., He, S., Liu, Z., Zhu, Z., Qiu, Y. and Zhu, F. (2015) Will Immediate Postoperative Imbalance Improve in Patients with Thoracolumbar/Lumbar Degenerative Kyphoscoliosis? A Comparison between Smith-Petersen Osteotomy and Pedicle Subtraction Osteotomy with an Average 4 Years of Follow-Up. *Spine*, **40**, E293-E300. <https://doi.org/10.1097/brs.0000000000000744>